

## ⇒ Case Report



# A Pregnant Woman With COVID-19, Diabetic Ketoacidosis, and Pancreatitis

Masoumeh Kheirandish<sup>1</sup>, Feysal Yousefzade<sup>2</sup>, Kimia Seddighi<sup>3</sup>, Mojtaba Khademi Bafrouie<sup>4</sup>, Arash Rahimi<sup>3\*</sup>

<sup>1</sup>Infectious and Tropical Diseases Research Center, Hormozgan Health Institute, Hormozgan University of Medical Sciences, Bandar Abbas, Iran

<sup>2</sup>Student Research Committee, Hormozgan University of Medical Sciences, Bandar Abbas, Iran

<sup>3</sup>Endocrinology and Metabolism Research Center, Hormozgan University of Medical Sciences, Bandar Abbas, Iran

<sup>4</sup>Department of Gastroenterology and Hepatology, Faculty of Medicine, Hormozgan University of Medical Sciences, Bandar Abbas, Iran

## Abstract

The novel coronavirus infection 2019 (COVID-19) is a pandemic viral disease officially named by World Health Organization (WHO) on March 11, 2020. It is mainly a respiratory disease but can involve other organs. Extrapulmonary presentations are broad and not well recognized. COVID-19 may trigger diabetic ketoacidosis (DKA) in a patient with adequately controlled diabetes. Pregnancy is an incomplete immune suppression status, making women more susceptible to infections, and the disease-related morbidity is higher during pregnancy. Herein, we present the case of a 23-year-old diabetic pregnant woman at 28 weeks gestation with acute pancreatitis, DKA, hypertriglyceridemia, with confirmed COVID-19 infection using polymerase chain reaction (PCR). She underwent antiviral therapy, adequate intravenous hydration, insulin infusion, and plasmapheresis in the intensive care unit (ICU). Her condition ultimately improved. COVID-19 with simultaneous pregnancy and diabetes mellitus increases the risk of metabolic disorders. Therefore, rapid diagnosis and adequate management would be considered.

**Keywords:** Case report, COVID-19, Diabetic ketoacidosis, Pancreatitis, Pregnancy

## \*Correspondence to

Arash Rahimi,  
Email: arashrahimi.article@gmail.com



Received March 8, 2021, Accepted: June 27, 2021, Published Online: December 29, 2021

## Background

Severe acute respiratory syndrome coronavirus 2 (SARS-CoV2) that causes COVID-19 disease started as a significant public health crisis worldwide at the end of 2019 (1). The infection severity is principally determined by severe pneumonia and acute respiratory distress (2). Early symptoms could include fever, fatigue, dry cough, anorexia, myalgias, dyspnea, and sputum production during pregnancy (3). Less common symptoms include anosmia and dysgeusia, along with nausea or diarrhea (4). Chronic conditions such as diabetes mellitus (DM), obesity, hypertension, cardiovascular disease, chronic lung or kidney disease, and cancer are risk factors for severe illness and mortality from COVID-19 (5). Studies revealed that COVID-19 might trigger diabetic ketoacidosis (DKA) and hyperglycemic hyperosmolar state (HHS) in patients with inadequately controlled DM. Moreover, it could be associated with newly diagnosed DM (6, 7).

Furthermore, the usual respiratory symptoms, different organ impairment has been reported, such as digestive, neurological, and cardiac symptoms. Therefore, the presenting symptoms seem to be more diversified than initially expected (1). COVID-19 appears to enter host

cells via the angiotensin-converting enzyme 2 (ACE2) receptor. ACE2 receptors express in the lungs, heart, brain, and digestive tract. It was also presented in the pancreas, where the COVID-19 could be bound to the receptors and lead to pancreatic damage during infection (8).

We reported a clinical case of a pregnant woman with COVID-19 infection who presented with DKA, hypertriglyceridemia, and pancreatitis.

## Case Presentation

The patient was a 23-year-old pregnant Iranian housewife (G3P2L2 at 28 weeks' gestation) who was referred to the emergency unit of Shahid Mohammadi hospital in Bandar Abbas in August 2020 due to abdominal pain. She was a known case of type 1 DM (T1DM) and dyslipidemia for 3 years. She had no exposure to a known case of COVID-19. She had no history of alcohol use. The history of recent traveling was negative. Her family history of DM and dyslipidemia was negative.

She presented with epigastric pain, nausea, vomiting (three times, containing food), and concomitant constipation. The epigastric pain was persistent, without radiation, improved with bending forward, worsened

with lying down. She denied any history of anorexia, shortness of breath, chest pain, dysuria, discoloration of urine, and flank pain. Vital signs at the time of admission included blood pressure (BP) 110/80 mm Hg, pulse rate (PR) 120 beats per minute, respiratory rate (RR) 25 per minutes, oral temperature (T) 37°C, and O<sub>2</sub> saturation of 100% in ambient air. On physical examination, the only positive point was mild epigastric tenderness. Fetal heart rate (FHR) was 164 beats per minute. The rest of the exam was normal. The laboratory evaluation showed, amylase 382 U/L, triglyceride (TG) 7664 mg/dL, cholesterol 979 mg/dL, and blood sugar (BS) 382 mg/dL. Venous blood gas (VBG) contained pH 7.2, HCO<sub>3</sub> 12, and Pco<sub>2</sub> 25. The rapid urinary test revealed the ketone body (Table 1).

Abdominal sonography showed evidence of pancreatitis such as pancreatic enlargement and inflammation, the presence of mild free fluid in the left pararenal space, and an incidentally discovered 4 mm gall stone. According to

the laboratory and imaging findings, diagnosis of DKA and pancreatitis was considered. On the second day of hospitalization, she was intubated due to respiratory distress and referred to our center. Intravenous hydration and insulin infusion that had started in the first hospital were continued until acidosis was subsided and blood sugar controlled. Because of hypotension, despite good hydration, we prescribed hydrocortisone 50 mg three times a day for only one day and discontinued when her blood pressure returned to normal. Eventually, she underwent plasmapheresis three times at the intensive care unit (ICU) (Figure 1), and serum TG level dropped dramatically. On the fourth day, the polymerase chain reaction (PCR) test for COVID-19 infection was positive, and antiviral therapy with remdesivir and Kaletra (lopinavir/ritonavir) was started, and she was transferred to COVID-19 ICU. Due to suitable oxygen saturation, relative contraindication in acute pancreatitis, and destructive effects on triglycerides and blood glucose, we did not start corticosteroids again. With improvement in the clinical situation, she was extubated and transferred to COVID ward on the seventh day of admission. Finally, the patient was discharged with a good general condition (RR: 18 and O<sub>2</sub> saturation 98%) with no significant lung involvement on a chest CT scan (Figure 2). Gemfibrozil 450 mg daily and omega-3 1000 mg two times a day were prescribed her after hospital discharge. She was completely well one month later during follow-up and eventually delivered a healthy baby without any complications.

## Discussion

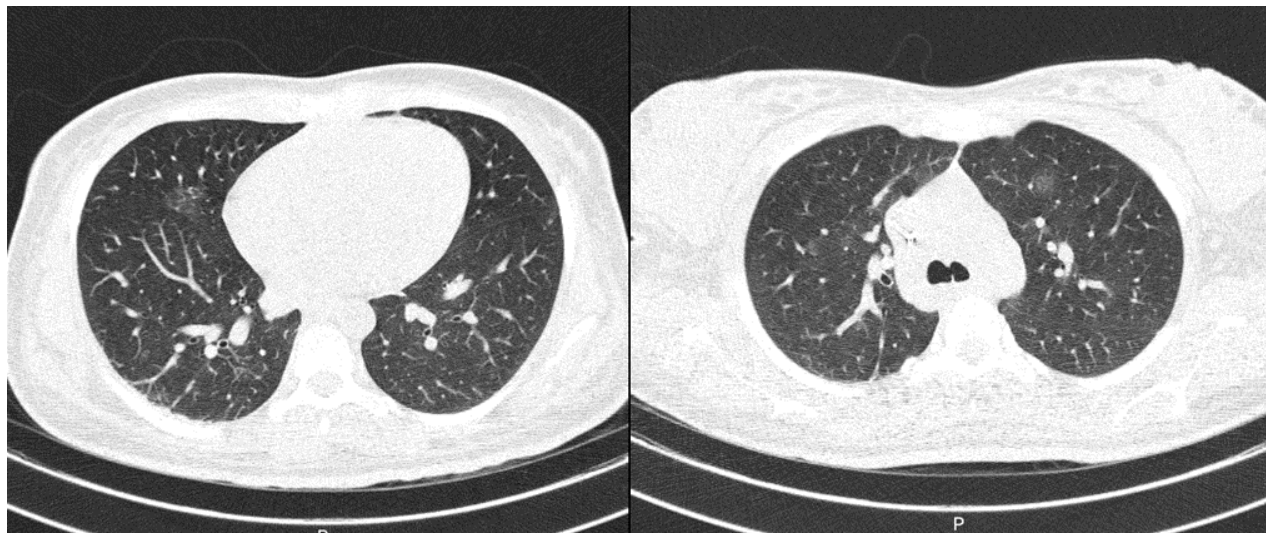
We presented the case of a young T1DM pregnant woman that was controlled by insulin therapy. She presented

**Table 1.** The Patient's Laboratory Tests

Lab Test	Result (Unit)	Reference Range
Alkaline phosphatase	231 (IU/L)	180-1200
Calcium	8.7 (mg/dL)	8.5-10.5
Phosphorus	3.4 (mg/dL)	2.9-5.1
Blood urea nitrogen (BUN)	13 (mg/dL)	5.5-23
Urea	27 (mg/dL)	30.8-48.1
Creatinine	0.7 (mg/dL)	0.5-1.4
Na	130 (mEq/L)	135-145
K	4.2 (mEq/L)	3.5-5.5
Mg	1.7 (mg/dL)	1.9-2.5
Triglyceride	7664 (mg/dL)	0-200
Cholesterol	979 (mg/dL)	0-200
WBC	6.4 (10 <sup>3</sup> /uL)	4-10
RBC	4.6 (10 <sup>6</sup> /uL)	4.2-5.2
Hb	12.2 (g/dL)	11-16
MCV	76.6 (fl)	80-96
Plt	299 (10 <sup>3</sup> /uL)	150-450
AST	26 (IU/L)	0-31
ALT	28 (IU/L)	0-31
Bilirubin-T	0.9 (mg/dL)	0.3-1.2
Bilirubin-D	0.2 (mg/dL)	<0.4
Amylase	382 (U/L)	Up to 100
Lipase	35 (U/L)	<60
LDH	909 (U/L)	120-460
Albumin	2.8 (g/dL)	3.5-5.5
CRP	51.8 (mg/L)	1-6
pH	7.2	7.35-7.45
Pco <sub>2</sub>	20 torr	35-45
Hco <sub>3</sub>	6.7 (mmol/L)	21-28
Po <sub>2</sub>	66 torr	>79
BS	382 (mg/dL)	<140



**Figure 1.** The patient's plasma was collected during plasmapheresis. It had a milky appearance.



**Figure 2.** Chest CT Scan (7<sup>th</sup> Admission Day), Mild Ground-Glass Opacity in the Left Upper Lobe and Right Middle Lobe.

with abdominal pain two days before admission and showed clinical, imaging, and laboratory evidence of pancreatitis, severe hyperglycemia, hypertriglyceridemia, and metabolic acidosis. Although lipase level was falsely normal because of significantly elevated TG, pancreatitis was the definite diagnosis.

Pregnancy is an incomplete immune suppression status, making women more susceptible to infections, and disease-related morbidity is higher during pregnancy (9). COVID-19 might present in pregnancy with the atypical presentation of clinical symptoms other than respiratory ones (10). There are two case reports of COVID-19 associated pancreatitis during pregnancy until now. The first case was a T1DM patient who presented with gastrointestinal symptoms without any predisposing factors for pancreatitis. She had no respiratory distress. Although the symptoms our patient presented with were similar to the first patient, but the concomitant conditions, including DKA and elevated TG were only present in our patient. Another case report was about a pregnant woman with respiratory symptoms and pancreatitis without other causes of pancreatitis in contrast to our case (10, 11). Though COVID-19 presents mainly with respiratory symptoms, the prevalence of gastrointestinal symptoms in patients with COVID-19 is estimated to be between 17% and 25% (12, 13). On the other hand, pancreatitis is a relatively common disease with an increasing prevalence in hospitalized patients with various causes, including gallstones, alcohol consumption, drugs, and virus-like mumps (14, 15). Currently, there is no conclusive evidence that COVID-19 is the cause of acute pancreatitis (16). However, the presence of ACE2 receptors in the pancreas, which are the binding site for the virus (16, 17), and concomitant metabolic disorders in patients with COVID-19, such as hyperglycemia and dyslipidemia, suggests that it could lead to pancreatitis directly by binding to the ACE2 receptors or indirectly through

hyperglycemia, DKA, and hypertriglyceridemia. While glycemia and lipid values were entirely under control on the second day of admission, it can be suggested that the virus-induced pancreatitis through various mechanisms illustrated previously. As a result, pregnancy is a high-risk condition, and metabolic disorders in COVID-19 during pregnancy should be considered and rapidly corrected. It is necessary to mention that we could not use imaging modalities to evaluate the pancreas because of pregnancy.

### Conclusion

We reported a case of DKA with acute pancreatitis in the context of severe hypertriglyceridemia in a diabetic pregnant patient with PCR confirmed COVID-19. Although the concurrency of multiple illnesses in a patient is rare, our case had multiple potentially severe and fatal conditions. The pathophysiology of COVID-19 associated pancreatitis has not been well known yet; it could be explained by the direct binding of the virus to ACE2 receptors and indirectly with a trigger of dysglycemia and hypertriglyceridemia.

### Availability of Data and Materials

The authors confirm that the data supporting this study's findings are available within the article.

### Authors' contributions

Study concept and design: AR, Drafting of the manuscript: MK & FY, Acquisition of data: KS, Critical revision of the manuscript: MK, Study supervision: MKB. All authors have read and approved the manuscript and ensure that is the case.

### Ethical approval

The study received ethics approval from the Ethical Committee of Hormozgan University of Medical Sciences under the ethics code: IR: HUMS.REC.1399.506, and it complies with the statements of the Declaration of Helsinki. Written informed consent for the publication of the article and any associated images were obtained from the patient.

### Conflict of Interests

The authors declare that they have no conflict of interest regarding the publication of this case report.

### Funding

This research did not receive any specific grant from funding agencies in the public, commercial, or not-for-profit sectors.

### Acknowledgments

We wish to sincerely thank our patient for allowing us to share her unique clinical presentation. We also appreciate expressing our gratitude to all the healthcare providers involved with her care, particularly the ICU ward.

### References

1. Tollard C, Champenois V, Delemer B, Carsin-Vu A, Barraud S. An inaugural diabetic ketoacidosis with acute pancreatitis during COVID-19. *Acta Diabetol.* 2021;58(3):389-91. doi: [10.1007/s00592-020-01624-3](https://doi.org/10.1007/s00592-020-01624-3).
2. Gonzalo-Voltas A, Uxia Fernández-Pérez-Torres C, Baena-Díez JM. Acute pancreatitis in a patient with COVID-19 infection. *Med Clin (Engl Ed).* 2020;155(4):183-4. doi: [10.1016/j.medcle.2020.05.010](https://doi.org/10.1016/j.medcle.2020.05.010).
3. Wang D, Hu B, Hu C, Zhu F, Liu X, Zhang J, et al. Clinical characteristics of 138 hospitalized patients with 2019 novel coronavirus-infected pneumonia in Wuhan, China. *JAMA.* 2020;323(11):1061-9. doi: [10.1001/jama.2020.1585](https://doi.org/10.1001/jama.2020.1585).
4. Giacomelli A, Pezzati L, Conti F, Bernacchia D, Siano M, Oreni L, et al. Self-reported olfactory and taste disorders in patients with severe acute respiratory coronavirus 2 infection: a cross-sectional study. *Clin Infect Dis.* 2020;71(15):889-90. doi: [10.1093/cid/ciaa330](https://doi.org/10.1093/cid/ciaa330).
5. Zhou F, Yu T, Du R, Fan G, Liu Y, Liu Z, et al. Clinical course and risk factors for mortality of adult inpatients with COVID-19 in Wuhan, China: a retrospective cohort study. *Lancet.* 2020;395(10229):1054-62. doi: [10.1016/s0140-6736\(20\)30566-3](https://doi.org/10.1016/s0140-6736(20)30566-3).
6. Li J, Wang X, Chen J, Zuo X, Zhang H, Deng A. COVID-19 infection may cause ketosis and ketoacidosis. *Diabetes Obes Metab.* 2020;22(10):1935-41. doi: [10.1111/dom.14057](https://doi.org/10.1111/dom.14057).
7. Palermo NE, Sadhu AR, McDonnell ME. Diabetic ketoacidosis in COVID-19: unique concerns and considerations. *J Clin Endocrinol Metab.* 2020;105(8):dgaa360. doi: [10.1210/clinem/dgaa360](https://doi.org/10.1210/clinem/dgaa360).
8. Liu F, Long X, Zhang B, Zhang W, Chen X, Zhang Z. ACE2 expression in pancreas may cause pancreatic damage after SARS-CoV-2 infection. *Clin Gastroenterol Hepatol.* 2020;18(9):2128-30.e2. doi: [10.1016/j.cgh.2020.04.040](https://doi.org/10.1016/j.cgh.2020.04.040).
9. Liang H, Acharya G. Novel corona virus disease (COVID-19) in pregnancy: What clinical recommendations to follow? *Acta Obstet Gynecol Scand.* 2020;99(4):439-42. doi: [10.1111/aogs.13836](https://doi.org/10.1111/aogs.13836).
10. Narang K, Szymanski LM, Kane SV, Rose CH. Acute pancreatitis in a pregnant patient with coronavirus disease 2019 (COVID-19). *Obstet Gynecol.* 2021;137(3):431-3. doi: [10.1097/aog.0000000000004287](https://doi.org/10.1097/aog.0000000000004287).
11. Rabice SR, Altshuler PC, Bovet C, Sullivan C, Gagnon AJ. COVID-19 infection presenting as pancreatitis in a pregnant woman: A case report. *Case Rep Womens Health.* 2020;27:e00228. doi: [10.1016/j.crwh.2020.e00228](https://doi.org/10.1016/j.crwh.2020.e00228).
12. Cheung KS, Hung IFN, Chan PPY, Lung KC, Tso E, Liu R, et al. Gastrointestinal manifestations of SARS-CoV-2 infection and virus load in fecal samples from a Hong Kong cohort: systematic review and meta-analysis. *Gastroenterology.* 2020;159(1):81-95. doi: [10.1053/j.gastro.2020.03.065](https://doi.org/10.1053/j.gastro.2020.03.065).
13. Inamdar S, Benias PC, Liu Y, Sejpal DV, Satapathy SK, Trindade AJ. Prevalence, risk factors, and outcomes of hospitalized patients with coronavirus disease 2019 presenting as acute pancreatitis. *Gastroenterology.* 2020;159(6):2226-8.e2. doi: [10.1053/j.gastro.2020.08.044](https://doi.org/10.1053/j.gastro.2020.08.044).
14. Al Mazrouei SS, Saeed GA, Al Helali AA. COVID-19-associated acute pancreatitis: a rare cause of acute abdomen. *Radiol Case Rep.* 2020;15(9):1601-3. doi: [10.1016/j.radcr.2020.06.019](https://doi.org/10.1016/j.radcr.2020.06.019).
15. Brindise E, Elkhatib I, Kuruvilla A, Silva R. Temporal trends in incidence and outcomes of acute pancreatitis in hospitalized patients in the United States from 2002 to 2013. *Pancreas.* 2019;48(2):169-75. doi: [10.1097/mpa.0000000000001228](https://doi.org/10.1097/mpa.0000000000001228).
16. de-Madaria E, Capurso G. COVID-19 and acute pancreatitis: examining the causality. *Nat Rev Gastroenterol Hepatol.* 2021;18(1):3-4. doi: [10.1038/s41575-020-00389-y](https://doi.org/10.1038/s41575-020-00389-y).
17. Kumaran NK, Karmakar BK, Taylor OM. Coronavirus disease-19 (COVID-19) associated with acute necrotising pancreatitis (ANP). *BMJ Case Rep.* 2020;13(9). doi: [10.1136/bcr-2020-237903](https://doi.org/10.1136/bcr-2020-237903).