

⇒ Case Report



Cardiac Tamponade in Patients with COVID-19 Infection; A Case Report

Hashem Jarineshin¹, Hossein montazerghaem², Atena Hatami¹, Hamid Nabibidhendi^{1*}

¹Anesthesiology, Critical Care and Pain Management Research Center, Hormozgan University of Medical Sciences, Bandar Abbas, Iran

²Cardiovascular Research Center, Hormozgan University of Medical Sciences, Bandar Abbas, Iran

Abstract

Coronavirus disease 2019 (COVID-19) is a novel pandemic that affects the cardiovascular system by various mechanisms. We report two cases of cardiac tamponade in patients with COVID-19, who underwent surgery and had different outcomes. Cardiac complications can occur in patients with COVID-19 that need special attention and may increase mortality and morbidity.

Keywords: COVID-19, Cardiac tamponade, Cardiovascular complications, Pericardial effusion, Case report

*Correspondence to

Hamid Nabibidhendi,
Email: Hamid_Nabi1986@yahoo.com



Received December 23, 2020, Accepted: February 24, 2021, Published Online: June 29, 2021

Background

The first case of coronavirus disease 2019 (COVID-19) was reported in December 2019, from Wuhan, China, with rapid spread worldwide. Soon after, COVID-19 became a public health emergency of international concern. The pathogen has been identified as a novel enveloped RNA beta-coronavirus and has been named severe acute respiratory syndrome coronavirus 2 (SARS-CoV-2) (1,2).

COVID-19 is an infectious disease caused by coronavirus 2 and manifests as severe acute respiratory syndrome with significant implications and high probability of cardiovascular involvement for the following reasons: first, patients with COVID-19 and underlying cardiovascular disease (CVD) have an increased risk of mortality and morbidity. Second, infection can cause multiple cardiovascular complications including myocardial injury, myocarditis, arrhythmias, pericarditis, pericardial effusion, and venous thromboembolism. Third, pharmacological and non-pharmacological managements of COVID-19 may have cardiac side effects. Fourth, attention and involvement of the health system with COVID-19 can disturb the rapid triage of patients without COVID-19 who refer with cardiac symptoms. Finally, the provision of cardiovascular care may put health care workers in a position of vulnerability as they become virus hosts or vectors of transmission (3). We report two cases of cardiac tamponade in patients with COVID-19 admitted to Shahid Mohammadi Hospital, Bandar Abbas, southern Iran that developed cardiac tamponade and referred to the operation room

for emergency surgery in the spring 2020.

Case Presentation

Case 1

The patient was a 42-year-old woman, a known case of breast cancer, that presented with dry cough, tachypnea, dyspnea, and low-grade fever. In physical exam, vital signs were stable, she had normal breathing sound and a muffled heart sound with friction rub. Polymerase chain reaction (PCR) was positive for SARS-CoV-2, So she was admitted to the COVID-19 ward.

Her laboratory data were as follows: WBC: 5 ($10^3/\mu\text{l}$), HB:9.1 (g/dl), HCT:29.7%, PLT:457 ($10^3/\mu\text{l}$), Neutrophil: 65.5%, Lymphocyte: 26.7%, ESR:35 (mm/hr), CRP:3+, LDH:335 (mg/dl), ferritin:259 (ng/ml), Urea:21 (mg/dl), Cr:0.8(mg/dl), Serum albumin: 3.3 (g/dl), 17(OH)Vit D:16.8 (ng/dl), Troponin-I: 3.7>>1.1 (pg/mL), ABG: PH: 7.44, PCO₂:43.6, PO₂: 17.4, HCO₃:29.7 BE:5.7, Blood group: O+. Other lab data were in the normal range.

Electrocardiogram (ECG) showed sinus rhythm with no significant STT (should be spelled out) change (Figure 1). In echocardiography she had LVEF: 50%, SPAP: normal, Mild MR, and significant pericardial effusion. In spiral chest CT scan, pericardial effusion plus pleural effusion with ground glass appearance and patchy infiltration were seen (Figure 2).

The patient was brought to the operation room and received oxygen with a facial mask. All of the surgical and anesthesiology team was fully protected against COVID-19 with shield and gown. The patient was completely monitored including electrocardiogram

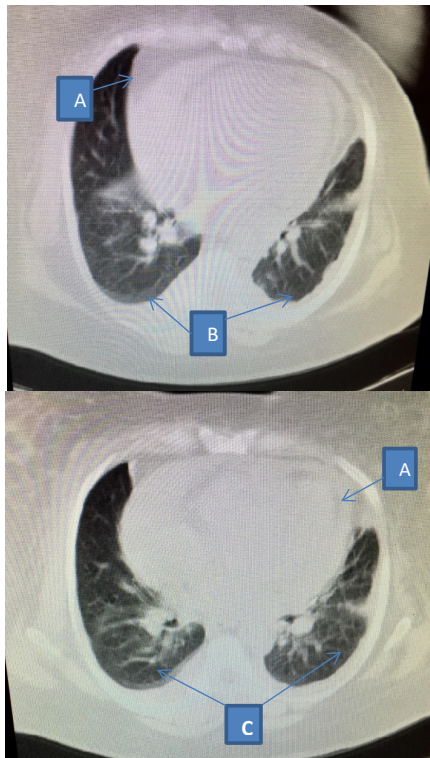


Figure 2. Illustrates pericardial effusion (A) plus pleural effusion (B), with ground glass appearance and patchy infiltration (C)

cases presented with cough, dyspnea, tachypnea, and fever. While these clinical manifestations are highly related to the inflammation of the respiratory system, these two cases provide evidence of cardiac involvement as a complication of the viral respiratory infection. This process can be asymptomatic or mild with few interstitial inflammatory cells, diagnosed through pathological findings or can present with overt symptoms with or without respiratory manifestations, similar to this report. A close clinical interplay between SARS-CoV2 and cardiovascular disease processes has been suggested by

data from early cohorts with COVID-19. Pre-existing cardiovascular disease has been associated with poor outcomes in affected patients with COVID-19 such as case 2, and though cases are limited, direct cardiovascular effects of the virus have been observed and may be associated with significant morbidity and mortality (4). Coexisting cardiac diseases, are common in patients with COVID-19 and these patients are at higher risk of morbidity and mortality (2). Furthermore, patients with COVID-19 often face diagnostic and therapeutic challenges because respiratory and cardiac pathologies are frequently associated and their clinical manifestations may be similar (2).

In this report, the first case had no history of cardiac disease and was younger, which may be the reason for the better outcome. The second case, was an elderly woman with coexisting heart disease and chronic kidney disease. All of these could be risk factors for adverse outcomes and increased mortality.

Many patients with COVID-19 (>20%) will have cardiac complications leading to increased mortality. Similar cardiovascular complications were also seen in 2003 during the previous SARS epidemic. The exact mechanism is still under study; however, the current belief is that SARS-CoV-2 causes cardiac complications through multiple mechanisms including increased cytokine release, hyperinflammation, adrenergic stimulation, and a hypercoagulable state. Viral infection is usually considered as one of the most common causes of myocarditis, especially in influenza and parvovirus B-19 infection (1). However, the cardiac complications of SARS-CoV-2 infection are less well-known. Myocarditis present as focal or global myocardial inflammation, necrosis, and finally ventricular dysfunction. Focal myocarditis is usually manifested with chest pain after an influenza-like syndrome, clinical evidence such as an acute coronary syndrome on electrocardiography

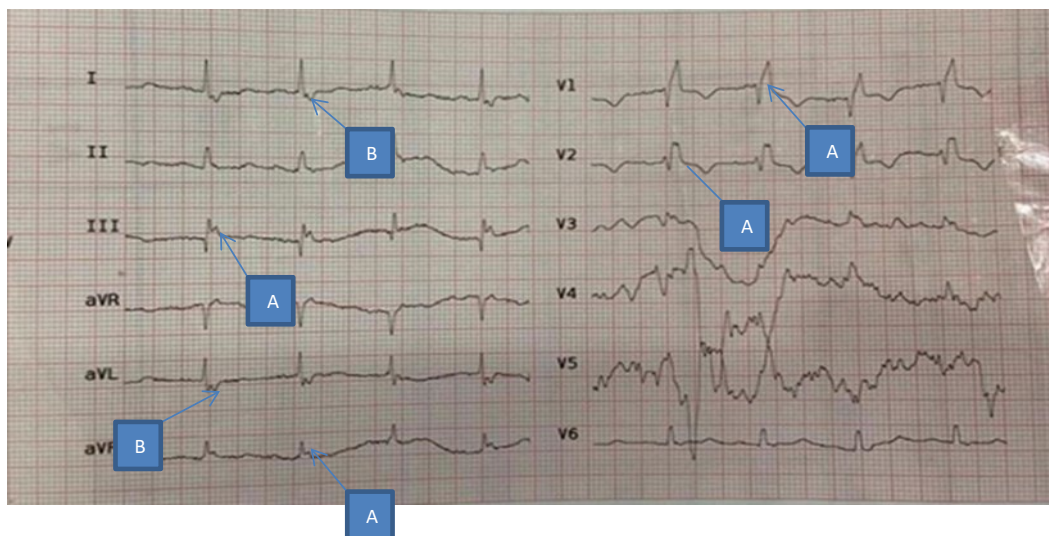


Figure 3. A normal sinus rhythm with concave infero-lateral ST elevation (A) and high lateral ST depression (B)

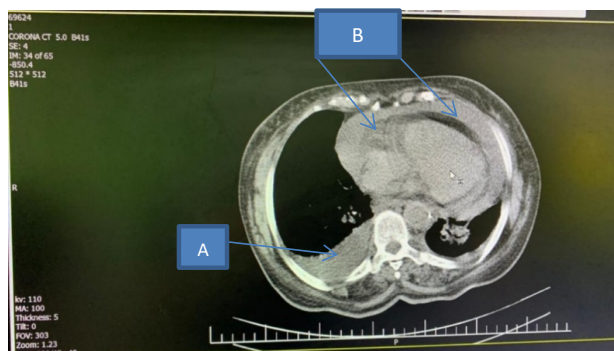


Figure 4. Illustrates large pleural effusion (A) in right lung plus massive pericardial effusion (B)

or laboratory testing and evidence of wall motion abnormalities without evidence of coronary artery involvement in coronary angiography (1,5). The pathogenesis of cardiac involvement in SARS-CoV-2 may reveal a process of replication and dissemination of the virus from the respiratory tract through the blood or the lymphatic system. However, to the best of our knowledge, there are no reports of influenza virus or coronavirus RNA in the heart, to date. Alternatively, SARS-CoV-2 could trigger an exaggerated inflammatory response that can cause myocardial injury, and this could favor the use of corticosteroids to attenuate inflammation, as in the present case (1,5). Evidence of significant inflammatory cell mediators, infiltration has been reported in the alveoli of patients with acute pneumonia associated with SARS-CoV-2 infection. Although the exact mechanisms are not certain, a potential binding to a viral receptor of the myocyte can justify the internalization and subsequent replication of the capsid proteins and the viral genome. Moreover, the onset of symptoms several days after the viral infection may reflect these possible mechanisms with a potential myocyte involvement, the activation of the immune and complement system, and, ultimately, clinical presentation of heart failure and cardiac complications (1,5).

It seems that SARS-CoV-2 is able to affect the heart and then potentially cause these cardiac complications: arrhythmias, myocardial infarction (with troponin elevation), STEMI, myocarditis with systolic dysfunction, pericarditis, myopericarditis, pericardial effusion +/- tamponade, pulmonary embolism. All these cardiac complications are significant and significantly increase morbidity and mortality (5,6).

The best technique for anesthesia management and surgical procedure of these patients is to perform surgery and pericardial window under local anesthesia with sedation especially in patients with unstable hemodynamic condition. However, in these cases we chose general anesthesia and tracheal intubation in coordination with

the surgical team and according to the medical history of the patients. Even though cardiac involvement is a rare extra-pulmonary manifestation of COVID-19, it should be kept in mind that intubation and positive pressure ventilation (PPV) can have deleterious hemodynamic effects in patients with cardiac tamponade (2,3)

Conclusion

Because of the increasing prevalence of COVID-19 and its various clinical manifestation, cardiovascular complications should be considered especially in patients with underlying diseases. It should also be noted that coexisting disorders including cardiac and kidney involvement as well as old age can be associated with high mortality and morbidity. Finally, these patients need to be managed carefully by multidisciplinary team work in the ICU under close observation and full monitoring. Research is still in process, and we are slowly learning about new signs and symptoms of the disease. Further related studies are necessary.

Funding

No funding was received.

Disclosure

The authors report no conflicts of interest in this work.

References

1. Inciardi RM, Lupi L, Zaccone G, Italia L, Raffo M, Tomasoni D, et al. Cardiac involvement in a patient with coronavirus disease 2019 (COVID-19). *JAMA Cardiol.* 2020;5(7):819-24. doi: [10.1001/jamacardio.2020.1096](https://doi.org/10.1001/jamacardio.2020.1096).
2. Asif T, Kassab K, Iskander F, Alyousef T. Acute pericarditis and cardiac tamponade in a patient with COVID-19: a therapeutic challenge. *Eur J Case Rep Intern Med.* 2020;7(6):001701. doi: [10.12890/2020_001701](https://doi.org/10.12890/2020_001701).
3. Driggin E, Madhavan MV, Bikdeli B, Chuich T, Laracy J, Biondi-Zoccai G, et al. Cardiovascular considerations for patients, health care workers, and health systems during the COVID-19 pandemic. *J Am Coll Cardiol.* 2020;75(18):2352-71. doi: [10.1016/j.jacc.2020.03.031](https://doi.org/10.1016/j.jacc.2020.03.031).
4. Walker C, Peyko V, Farrell C, Awad-Spirtos J, Adamo M, Scrocco J. Pericardial effusion and cardiac tamponade requiring pericardial window in an otherwise healthy 30-year-old patient with COVID-19: a case report. *J Med Case Rep.* 2020;14(1):158. doi: [10.1186/s13256-020-02467-w](https://doi.org/10.1186/s13256-020-02467-w).
5. Dalen H, Holte E, Guldal AU, Hegvik JA, Stensaeth KH, Braaten AT, et al. Acute perimyocarditis with cardiac tamponade in COVID-19 infection without respiratory disease. *BMJ Case Rep.* 2020;13(8). doi: [10.1136/bcr-2020-236218](https://doi.org/10.1136/bcr-2020-236218).
6. Hakmi H, Sohail A, Brathwaite C, Ray B, Abrol S. Cardiac tamponade in COVID-19 patients: management and outcomes. *J Card Surg.* 2020;35(11):3183-90. doi: [10.1111/jocs.14925](https://doi.org/10.1111/jocs.14925).