

Results of Pyeloplasty in patients with Ureteropelvic Junction Obstruction in Pediatric Surgery Center in Bandar Abbas

Seyyed Mohammad Vahid Hosseini¹ Mehrdad Sayadinia² Behnam Hanaei² Shahram Zare³ Maryam Esteghamati⁴ Ahmad Hanaei⁵

Department of Pediatrics Surgery¹, Hormozgan University of Medical Sciences, Bandar Abbas, Iran. Department of Surgery², Hormozgan University of Medical Sciences, Bandar Abbas, Iran. Department of Community Medicine³, Hormozgan University of Medical Sciences, Bandar Abbas, Iran. Department of Pediatrics⁴, Hormozgan University of Medical Sciences, Bandar Abbas, Iran. Medical Student⁵, Hormozgan University of Medical Sciences, Bandar Abbas, Iran.

(Received 20 Apr, 2014)

Accepted 9 Apr, 2017)

Original Article

Abstract

Introduction: Ureteropelvic junction obstruction (UPJO) is associated with inadequate urine drainage from renal pelvis into ureter. UPJO results from incomplete recanalization of proximal ureter during fetal period which finally leads to hydrostatic distention of renal pelvis and calyces. Diagnosis is based on clinical symptoms, ultrasound, and diuretic isotopic renogram. Various surgical methods are used for treatment including dismembered pyeloplasty which is associated with better outcomes.

Methods: Patients with UPJO who were undergone pyeloplasty (in an interval of 2.5 years) were followed and their pre- and postoperative ultrasounds and diuretic isotopic renograms were compared in terms of renal pelvis AP diameter in ultrasound and renal flow rate after injection of diuretics in renal scan.

Results: Of 22 patients included in this study, postoperative renal pelvis AP diameter and renal flow rate were reduced in one patient, who then underwent reoperation with a diagnosis of recurrence. Despite normal postoperative renal flow scan, renal pelvis AP diameter in ultrasound had no significant change after surgery than before surgery in 4 patients (mean change 0.5 mm). Pelvis AP diameter was slightly increased in 2 patients (mean change 1.8 mm). Pelvis AP diameter was increased in the remaining 15 patients after surgery (mean 11.3 mm). Renal flow was increased following administration of diuretics in all patients ($P < 0.001$).

Conclusion: The present study showed that ultrasound based on renal pelvis AP diameter cannot definitely predict outcomes of patients with UPJO and renal scan is a reliable tool for evaluation of patients clinical and renal function improvement.

Key words: Urinary Tract, Ureteropelvic Junction Obstruction, Radioisotoperenography

Citation: Hosseini MV, Sayadinia M, Hanaei B, Zare S, Esteghamati M, Hanaei A. Results of Pyeloplasty in patients with Ureteropelvic Junction Obstruction in Pediatric Surgery Center in Bandar Abbas. Hormozgan Medical Journal 2017;21(1):36-41.

Introduction:

UPJO is associated with inadequate drainage of urine from renal pelvis or ureter, resulting in

hydrostatic distention of renal pelvis and calyces. Elevated intracalyceal pressure and stasis of urine in urinary collecting tubules lead to progressive renal damage. The incidence of UPJO is estimated

approximately 1 in 5,000 live births being twice more common in boys and occurring on the left side in 2/3 of the cases. Bilateral UPJO occurs in 5-10% of cases (1).

UPJO is the result of incomplete recanalization of upper ureter during fetal development. Other intrinsic causes of UPJO include ureteral valves, polyp, and leiomyoma. Histological findings in UPJO include the reduction or absence of smooth muscle fibers in UPJ.

UPJO can be acquired, usually after a high grade vesicoureteral reflux, ureterostomy, and decompression of dilated urinary tract.

Currently, most cases of cervical dilatation and obstruction can be diagnosed in the fetus during pregnancy through prenatal ultrasound.

A smaller percentage is detected with an abdominal mass or urinary tract infection or along with other anomalies (such as Vacterl syndrome).

Older children may experience non-localized and periodic abdominal pain along with nausea, and hence many of them are visited by a pediatric gastroenterologist.

Hematuria may occur after minor trauma or vigorous exercise.

Episodic flank pain with diuresis is common in older children but uncommon in infants.

When ureteropelvic junction obstruction is detected before birth, the first evaluation should begin at 10-14 days after the birth. Infants receive 10 mg/kg preventive oral amoxicillin and undergo abdominal ultrasound which shows renal pelvis and calyx dilatation as well as renal parenchymal thinning. Ultrasound is also used to evaluate the contralateral kidney as well as bladder and ipsilateral distal ureter in terms of ureterovesical junction obstruction (2).

VCUG (voiding cystourethrography) has been done previously for all UPJOs, but advances in perinatal ultrasound showed that VCUG is not necessary for all cases, because only 5-30% of patients have reflux with dilatation and a high percentage of them recover without any complication and infection. Diuretic isotopic renogram is a very useful technique for evaluation of hydronephrosis, renal function, and renal drainage.

Technetium 99m-labelled diethylenetriamine penta-acetic acid (^{99m}Tc-DTPA) is the injection

compound. Before performing the scan, patients are hydrated with 15 ml/kg normal saline and a urinary catheter is inserted into the bladder, the bladder is emptied, and urine output is monitored.

After maximization of the hydronephrotic kidney activity, 1mg/kg furosemide diuretic is injected and the activity of the contrast medium is monitored for 30 minutes and the quantitative results are recorded. UPJO is diagnosed when more than 50% of contrast medium is remained in the renal pelvis 20 minutes after diuretic injection ($t_{1/2} > 20$).

False-positive results may be obtained when the patient is dehydrated, the bladder is distended, and the involved renal pelvis is significantly dilated.

Intermittent obstruction and pain may be considered reliable indications for surgical intervention.

However, there is no comprehensive definition for obstruction.

Decreased renal function, delayed drainage, and progression of pelvic dilatation in ultrasound are potential indications for surgery (3).

Relying only on the morphology of pelvis dilation level revealed by ultrasound or excretory urography is not enough for surgery, because many of these anomalies may completely disappear without surgery.

Infant hydronephrosis may be justified with physiological polyuria and normal kinking or folding in the ureter. Decreased kidney function in the presence of obstruction in ultrasound is an indication for surgical treatment.

Many centers suggest surgery when hydronephrotic kidney function is reduced by 35-40%.

Extensive long-term study shows that a small percentage (15-20%) with renal functions of 35-40% will require surgery in the future because of reduced kidney function, urinary tract infection, or unexplained abdominal pain.

In a child with acute pain or infection for the first time, it is recommended to wait for 1-2 weeks until the inflammation subsides.

Preoperative percutaneous drainage to prevent sepsis is rarely necessary.

Nephrectomy should be done when the macroscopic appearance of renal parenchyma is

dysplastic or frozen section analysis shows dysplasia, although they are very rare in UPJO (4).

Given the difficult approach from the flank, the anterior extra peritoneum approach is often used which includes an incision from rectus edge to the tip of twelfth rib. Obstruction can be observed after exploring the retro peritoneum and reaching the kidney. Posterior lobotomy is another incision which provides a direct view of UPJ.

Kidney does not require mobilization and ureter and renal pelvis can be raised to the incision level. Old surgical techniques of UPJO include Foley YV plasty and Culp spiral flap; they are still used in the cases of malrotation, fusion anomaly, or long narrow segment.

Dismembered technique is developed as the best operation method. In the dismembered pyeloplasty, renal pelvis and upper ureter are mobilized and the ureter is dissected only in the lower portion of obstruction and is spatulated in the lateral of obstruction segment. If this obstruction segment is long, a part of the renal pelvis should be removed to prevent postoperative obstruction.

Excessive manipulation of the tissue may cause edema, pyeloplasty should be done without diversion. Anastomosis can be performed with PDS 6-0, and full irrigation should be performed to remove the clot before the anastomosis.

Pyeloplasty is done without nephrostomy tube or stent. Even a leak of anastomosis will not have serious consequences (5).

A Penrose drain can be placed near the anastomosis during operation and is drawn after 48 hours, but if the drainage is continued, the child can be discharged with the drain.

Pyeloplasty have successful outcomes. The recurrence rate of UPJO after surgery is about 1% and in nephrectomy, is less than 2%.

The most frequent earliest postoperative complications are urinary extravasation and delayed drainage from anastomosis, and if continued for more than 14 days, a second pyelography should be done. If leakage is significant, a percutaneous nephrostomy or stent should be implemented, although there is the possibility of delayed opening of anastomosis and 80% of these cases will be reopened within 3 months (6).

Secondary obstruction or first operation failure due to scarring and fibrosis of operation site is not

associated with anastomosis and is secondary to angulation of the ureter due to renal malrotation or stenosis of distal ureteral to anastomosis. This can be repaired through an open surgical procedure similar to the first operation or through an endoscopic approach.

Assessment of the anastomosis should be done 2-3 months after the first operation. A second assessment is recommended within 12 to 24 months after which the occurrence of complications in the absence of signs is unlikely (7).

Methods:

In this prospective clinical trial, patients with UPJO who were visited from 3/21/2011 in the specialized center of Bandar Abbas hospital and their diagnosis had been confirmed by scan and ultrasound were included in this study. After confirmation of diagnosis, all patients underwent dismembered pyeloplasty and were followed after discharge.

Depending on the case and signs, ultrasound and renal scan were done after 2-6 months and the patients improvements as well urinary outflow of more than 50% in scan were compared. Factors such as pelvis diameter in ultrasound and the recurrence rate were also determined. Patients with incomplete scan and ultrasound were excluded, and finally, 22 patients were evaluated.

At first, the basic data of patients including age and medical history were studied and the results of scan and ultrasound were recorded in the corresponding forms.

In cases where the progressive hydronephrosis due to calyx severe stricture might cause renal damage, a nephrostomy tube was placed under general anesthesia.

Surgery was performed under general anesthesia, after preparation of the surgical area with betadine solution and draping the site, the skin was incised transversely from the rectus edge to the tip of twelfth rib.

Obstruction was observed after exploring the retro peritoneum and reaching the kidney. Renal pelvis and upper ureter were mobilized and the ureter was dissected only in the lower portion of obstruction and was spatulated in the lateral of obstruction segment. If the obstruction segment was

long, a part of the renal pelvis was removed to prevent postoperative obstruction. A J-stent was inserted at anatomists site with the tip at the kidney and the end in the bladder. Anastomosis was sutured with PDS 6-0 and the surgery site was checked in terms of hemostasis. If required, a Penrose drain was placed in the operation site and the abdomen was closed in the usual way. The patients were finally transferred to the ward, the drains were removed after 48 hours and the patients were discharged.

Two weeks after the surgery, J-stent was removed. In case of clinical or laboratory evidence of urinary tract infection, the patients received oral cephalexin. After 2-6 months, the patients were followed with renal scan and the recovery rate based on more than 50% outflow after diuretic injection was determined. Post-operative ultrasound was also performed to measure pelvis diameter and stenosis.

Results:

Of all patients with a diagnosis of UPJO who visited Children's Hospital in Bandar Abbas from 2011 to 2013 and underwent dismembered pyeloplasty, those with incomplete pre- and postoperative renal scan and ultrasound and those with impossible follow-up were excluded and finally, 22 patients were enrolled in the study.

Preoperative ultrasound of all patients showed moderate and severe hydronephrosis with a mean AP pelvis diameter of 9.4 mm.

Preoperative scan in all 22 patients showed less than 40% renal flow after injection of diuretic, with a mean of 24.07.

Postoperative ultrasound within 2-6 months revealed 5 cases of mild hydronephrosis and 1 case of moderate hydronephrosis with a mean pelvis AP diameter of 20.7 mm which was increased averagely 11.3 mm compared with before surgery.

Postoperative scan was performed 2-6 months after surgery, and renal flow after diuretic injection was more than 50% (mean 60.5) in 21 patients. In one case, postoperative ultrasound showed moderate hydronephrosis with postoperative renal flow of 24.5 in the scan. With the diagnosis of recurrence, this case underwent a second operation, the scan after which showed a flow rate of 60.6.

Postoperative urinary tract infection was observed in 5 patients which was recovered without complication with proper treatment. Despite normal renal flow in postoperative scan in 4 patients, renal pelvis AP diameter in postoperative ultrasound was not significantly changed after surgery compared with before surgery (mean change 0.5 mm). Pelvis AP diameter was slightly increased in 2 patients (mean change 1.8 mm). Pelvis AP diameter increased significantly after surgery in the remaining 15 patients. The overall mean of changes in pelvis diameter was 11.3 mm for all patients. However, renal flow following diuretic injection was increased in all patients. Statistical analyses were performed using paired *t*-test and appropriate tests for duplicate data, and according to the analysis, results depicted in the attached table were considered significant with P -value < 0.05 ($P < 0.001$).

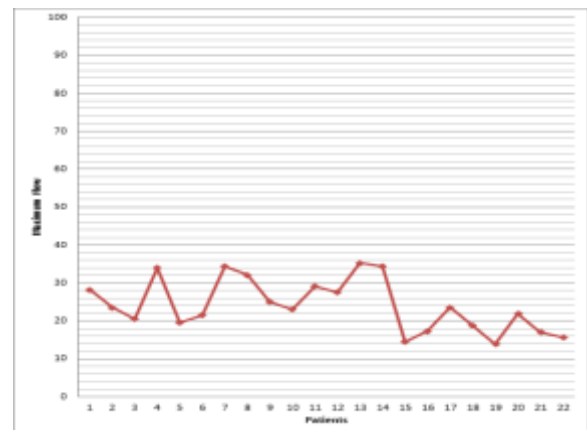


Figure 1. Renal flow rate in patients before surgery

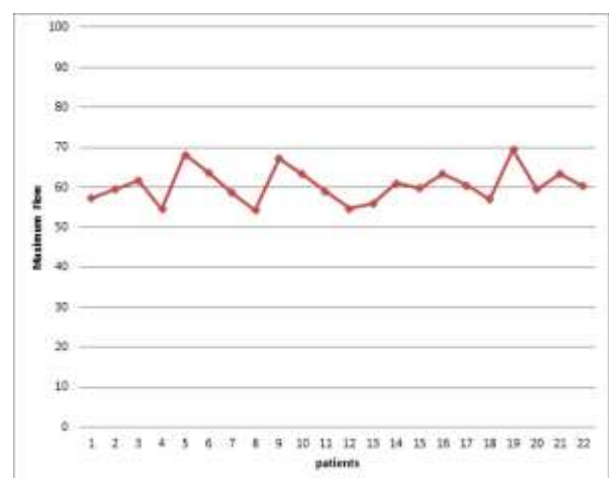


Figure 2. Renal flow rate in patients after surgery

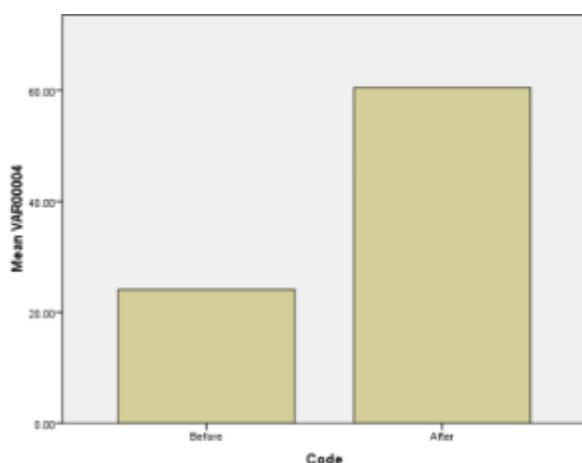


Figure 3. Comparison of the mean flow distribution in patients before and after surgery

Conclusion:

In this study, 22 patients with UPJO underwent dismembered pyeloplasty and were followed by ultrasound and renal scan. Comparison of preoperative and postoperative results showed one case of recurrence with hydronephrosis, renal pelvis stenosis, and reduced renal pelvis AP diameter in ultrasound and reduced flow in scan. With the diagnosis of recurrence, the patient underwent a second surgery. Finally, in the second operation, the increase in pelvic diameter was measured 21 mm. In 6 patients, ultrasound showed a small increase in pelvis diameter (with an average range of 0.5 mm for 4 patients and 1.8mm for 2 patients). But the renal flow rate of these 6 patients showed clinical improvement which was not statistically significant according to change range. Renal pelvis AP diameter was obviously increased in the remaining 15 patients that was consistent with the clinical improvement and postoperative renal scan.

Postoperative renal scan showed normal renal function in 21 patients after the first operation, and in 1 patient after the second operation; this is comparable with the international standards of UPJO outcomes (less than 1% recurrence and progression to nephrectomy).

Our analyses in this study showed that ultrasound based on renal pelvis AP diameter cannot definitely predict the final outcome of UPJO patients and the results of isotope scan are reliable for clinical remission and renal function of patients.

References:

1. Braga LH, Pace K, DeMaria J, Lorenzo AJ. Systematic review and meta-analysis of robotic-assisted versus conventional laparoscopic pyeloplasty for patients with ureteropelvic junction obstruction: effect on operative time, length of hospital stay, postoperative complications, and success rate. *European urology*. 2009;56(5):848-858.
2. Taha MA, Shokeir AA, Osman HG, El AE, Farahat SE. Diagnosis of ureteropelvic junction obstruction in children: role of endothelin-1 in voided urine. *Urology*. 2007;69(3):560-564.
3. Tan BJ, Smith AD. Ureteropelvic junction obstruction repair: when, how, what?. *Current Opinion in Urology*. 2004;14(2):55-59.
4. Calisti A, Perrotta ML, Oriolo L, Patti G, Marrocco G, Miele V. Functional outcome after pyeloplasty in children: impact of the cause of obstruction and of the mode of presentation. *European Urology*. 2003;43(6):706-710.
5. Varkarakis IM, Bhayani SB, Allaf ME, Inagaki T, Ong AM, Kavoussi LR, et al. Management of secondary ureteropelvic junction obstruction after failed primary laparoscopic pyeloplasty. *The Journal of Urology*. 2004;172(1):180-182.
6. Bouzada MC, Oliveira EA, Pereira AK, Leite HV, Rodrigues AM, Fagundes LA, Gonçalves RP, Parreiras R. Diagnostic accuracy of postnatal renal pelvic diameter as a predictor of uropathy: a prospective study. *Pediatric radiology*. 2004;34(10):798-804.
7. Amling CL, O'hara SM, Wiener JS, Schaeffer CS, King LR. Renal ultrasound changes after pyeloplasty in children with ureteropelvic junction obstruction: long-term outcome in 47 renal units. *The Journal of Urology*. 1996;156(6):2020-2024.

بررسی نتایج عمل ترمیمی (pyloplasty) در بیماران مبتلا به انسداد محل اتصال لگنچه به حالب (upjo) در مرکز جراحی کودکان بندر عباس

سید محمد وحید حسینی^۱، مهرداد صیادی^۲، نیل^۳، بهنام حنایی^۴، شهرام زارع^۳، مریم استقامتی^۴، احمد حنایی^۵

^۱ گروه جراحی اطفال، دانشگاه علوم پزشکی هرمزگان، بندرعباس، ایران. ^۲ گروه جراحی، دانشگاه علوم پزشکی هرمزگان، بندرعباس، ایران. ^۳ گروه پزشکی اجتماعی، دانشگاه علوم پزشکی هرمزگان، بندرعباس، ایران. ^۴ گروه اطفال، دانشگاه علوم پزشکی هرمزگان، بندرعباس، ایران. ^۵ دانشجوی پزشکی، دانشگاه علوم پزشکی هرمزگان، بندرعباس، ایران.

مجله پزشکی هرمزگان سال بیست و یکم شماره اول ۹۶ صفحات ۴۱-۳۶

چکیده

مقدمه: در *upjo* درناژ کافی ادرار لگنچه کلیه به حالب وجود دارد که به علت نقص در *recanalizing* شدن کامل پروگزیمال حالب در طول دوره جنینی می‌باشد و نهایتاً دیستانسیون هیدروستاتیک لگنچه کلیه و کالیس‌های داخل کلیوی رخ می‌دهد. تشخیص بر اساس علایم بالینی و سونوگرافی و اسکن *diuretic isotopic renogram* می‌باشد. روش‌های جراحی متعددی جهت درمان به کار برده که از این بین، روش *pyloplasty (dismembered)* با نتایج بهتری همراه بوده است.

روش کار: بیمارانی که با تشخیص *upjo* تحت عمل جراحی *pyloplasty* قرار گرفتند (در فاصله زمانی ۲/۵ سال) مورد پیگیری قرار گرفته و نتایج سونوگرافی و اسکن دیورتیک کلیوی قبل از عمل و بعد از عمل آنها با همدیگر مقایسه شد که شامل قطر *A-P* لگنچه کلیه و سونوگرافی و درصد فلوی کلیوی بعد از تزریق دیورتیک در اسکن کلیوی آنها بود.

نتایج: از ۲۲ بیمار وارد شده در این مطالعه، ۱ مورد قطر *A-P* لگنچه کلیوی بعد از عمل کاهش و درصد فلوی کلیوی پس از عمل کاهش پیدا کرده بود که با تشخیص عود تحت عمل جراحی مجدد قرار گرفت. در ۴ بیمار با وجود فلوی کلیوی نرمال در اسکن بعد از عمل قطر *A-P* لگنچه کلیه در سونوگرافی بعد از عمل تغییر محسوس به نسبت قبل از عمل نداشت (میانگین تغییرات ۰/۵ میلی متر)، در ۲ بیمار قطر *A-P* لگنچه افزایش مختصری پیدا کرده بود (میانگین تغییرات ۱/۸ میلی متر)، در ۱۵ بیمار باقیمانده قطر *A-P* لگنچه بعد عمل افزایش نشان داد (میانگین کلی ۱۱/۳ میلی متر) - در تمامی بیماران فلوی کلیوی به دنبال تزریق دیورتیک افزایش پیدا کرده بود ($P < 0.01$).

نتیجه‌گیری: بررسی‌های ما در این مطالعه نشان داد که بررسی‌های سونوگرافی بر اساس اندازه قطر *A-P* لگنچه کلیه نمی‌تواند قطعاً پیشگویی‌کننده *outcome* بیماران *upjo* باشد و نتایج اسکن کلیوی معیار قابل اعتمادی جهت بهبود بالینی و عملکرد کلیوی بیماران می‌باشد.

کلیدواژه‌ها: مجاری ادراری، انسداد محل اتصال لگنچه به حالب، اسکن ایزوتوپ کلیوی

نویسنده مسئول:

دکتر بهنام حنایی

گروه جراحی بیمارستان شهیدمحمدی

دانشگاه علوم پزشکی هرمزگان

بندرعباس - ایران

تلفن: +۹۸ ۹۱۷۳۶۱۸۷۸۲

پست الکترونیکی:

Iludpars@yahoo.com

نوع مقاله: پژوهشی

دریافت مقاله: ۹۳/۱/۳۱ اصلاح نهایی: ۹۵/۱۲/۱۵ پذیرش مقاله: ۹۶/۱/۲۰

ارجاع: حسینی سید محمد وحید، صیادی نیا مهرداد، حنایی بهنام، زارع شهرام، استقامتی مریم، حنایی احمد. بررسی نتایج عمل ترمیمی (pyloplasty) در بیماران مبتلا به انسداد محل اتصال لگنچه به حالب (upjo) در مرکز جراحی کودکان بندرعباس. مجله پزشکی هرمزگان ۱۳۹۶؛ ۲۱(۱): ۴۱-۳۶.