

⇒ Case Report



Nasal Chondromesenchymal Hamartoma: An Adult Case Report

Mehdi Askari^{1*}, Maryam Kadivar², Saleh Mohebbi³, Ghazal Zoghi⁴¹Department of Otolaryngology Head and Neck Surgery, Faculty of Medicine, Hormozgan University of Medical Sciences, Bandar Abbas, Iran²Department of Pathology, Iran University of Medical Sciences, Tehran, Iran³Department of Otolaryngology Head and Neck Surgery, Iran University of Medical Sciences, Tehran, Iran⁴Endocrinology and Metabolism Research Center, Hormozgan University of Medical Sciences, Bandar Abbas, Iran**Abstract****Background:** Nasal chondromesenchymal hamartoma (NCMH) is a rare benign tumor almost always found in children. NCMH was first described by McDermott in 1998. To the best of our knowledge, about 50 NCMH cases have been reported worldwide with very few adult cases and no long-term follow-ups.**Case Presentation:** Here, we report a 43-year-old woman who referred to the Otolaryngology Clinic of Payambar Azam Hospital, Bandar Abbas, Iran, in 2008, with a one-year history of progressive left-sided nasal obstruction that had not relieved with topical nasal decongestants and steroid sprays. A unilateral left-sided nasal soft-tissue mass was found upon examination. Histological and immunohistochemical analyses were consistent with NCMH. Trans-nasal endoscopic excision showed good results and no sign of recurrence has been observed after 12 years of regular follow-up.**Conclusion:** Awareness of imaging and immunohistochemical characteristics of NCMH combined with the probability of presentation in the adult population are necessary for correct diagnosis and adequate therapy.**Keywords:** Case report, Hamartoma, Nose neoplasm, Adult***Correspondence to**Mehdi Askari,
Email: mehdi.askari913@gmail.com

Received March 4, 2021, Accepted: June 13, 2021, Published Online: September 29, 2021

Background

Hamartomas are malformations made up of excessive growth of tissues in places unrelated to their origin. They are common in the kidney, chest wall, lung, skin, and gastrointestinal tract, yet uncommon in the head and neck. Rarely, they have been reported in the oral cavity, tongue, nasal cavity, nasopharynx, eustachian tube, hypopharynx, and larynx (1). Nasal chondromesenchymal hamartoma (NCMH) is a benign lesion of the nasal cavity with unknown pathogenesis, mostly described in young infants. McDermott and colleagues coined the term NCMH for a mass made up of mesenchymal and chondroid elements developing in young children's nasal cavities (2). To date, about 50 cases have been reported. This neoplasm predominantly presents in infants under the age of one; however, there are nine adult case reports including ours (3). We aimed to present a rare case of NCMH in an adult patient.

Case Presentation

A 43-year-old Iranian woman with one-year history of progressive left-sided nasal obstruction presented to the Otolaryngology Clinic of Payambar Azam Hospital, Bandar Abbas, Iran, in 2008. She had no history of

rhinosinusitis or allergic symptoms and topical nasal decongestants and steroid sprays did not relieve her symptoms. Her medical history was not significant. Upon physical examination a large polypoid mass was observed that was obstructing her left mid-nasal cavity. Nasal endoscopy revealed that the mass had rose superior to the left inferior turbinate with extension to the middle meatus and medial displacement of the middle turbinate. Head and neck examination were normal. Computed tomography (CT) scan (without contrast) of the nose and sinuses (Figures 1A and 1B), showed a left-sided soft-tissue lesion in the nasal cavity measuring 3.5×4×4.2 cm. The mass laterally displaced the medial wall of left maxillary sinus, contacted the septum medially, obstructed the left choana posteriorly, and extended superiorly. There was no sign of erosion in the bony compartments surrounding the mass but the adjacent bones had become thin by pressure remodeling. Complete trans-nasal endoscopic excision was performed. Intraoperative examination showed a mass in the middle meatus arising from the intact nasal roof that was distinct from the left middle and inferior turbinates. The anterior ethmoidal area was partly occupied by the mass and the middle turbinate was very thin and loose. It also caused obstruction in the

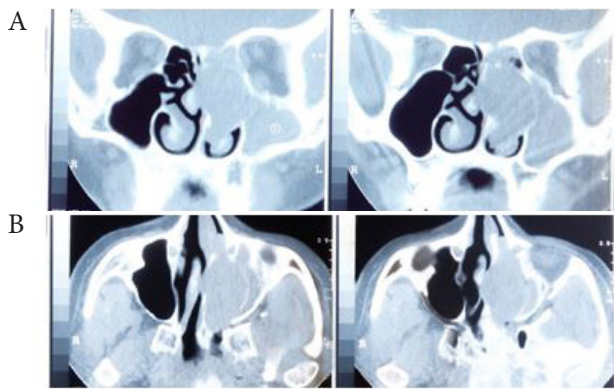


Figure 1. CT images (without contrast) (A) coronal and (B) axial views of the nose and sinuses demonstrate a left nasal soft tissue lesion. Lateral displacement of medial antral wall is due to the thinning of adjacent bones caused by pressure remodeling. Opacification of the left maxillary sinus is due to the obstruction by the mass.

drainage pathways of the left maxillary and frontal sinuses and accumulation of mucoid materials in these sinuses. A polypoid lesion made up of nodules of variable sizes was found in microscopic examination of the specimen which predominantly consisted of cellular mesenchymal stroma surrounding mature hyaline cartilage. This also included myxoid features (Figure 2A) and aneurysmal bone cyst-like areas filled by blood (Figure 2B).

In this study the patient was examined endoscopically every two months in the first year after surgery, then every four months up to five years. Since then, routine examinations were performed every six months. If the patient showed signs of obstruction, runny nose, etc. on either side for more than two to three weeks, a radiographic examination would be performed. Within 12 years, the patient's nose and sinuses were evaluated for tumor regrowth or the possibility of malignant degeneration. The last CT scan showed complete resolution.

Discussion

NCMH, with characteristic clinicopathological features, is a benign tumor that usually occurs in infants' nasal cavity. It resembles the mesenchymal hamartoma of the chest wall which is a similar entity involving the chest wall of neonates and children (2). Reported patients are mostly under the age of one year with a mean age of 9.6 (range: 1 day-70 years), and the male/female ratio is 2.5/1 (3). At the time of diagnosis in 2008, our patient was the 3rd adult case among 27 documented cases in the literature, but we postponed the report to achieve regular, long-term follow-up results. Currently, this case is the 9th adult case of NCMH. This neoplasm, usually presents with nasal and ocular signs and symptoms. Based on the literature review, nasal complaints include nasal mass, obstruction, rhinorrhea, epistaxis, hyposmia, and recurrent sinusitis (1,3). Ophthalmological signs include oculomotor disturbance, hypotropia, exotropia, strabismus, and visual disturbance (4). Similarly, the main complaint in our case was left-sided nasal obstruction and minimal pressure

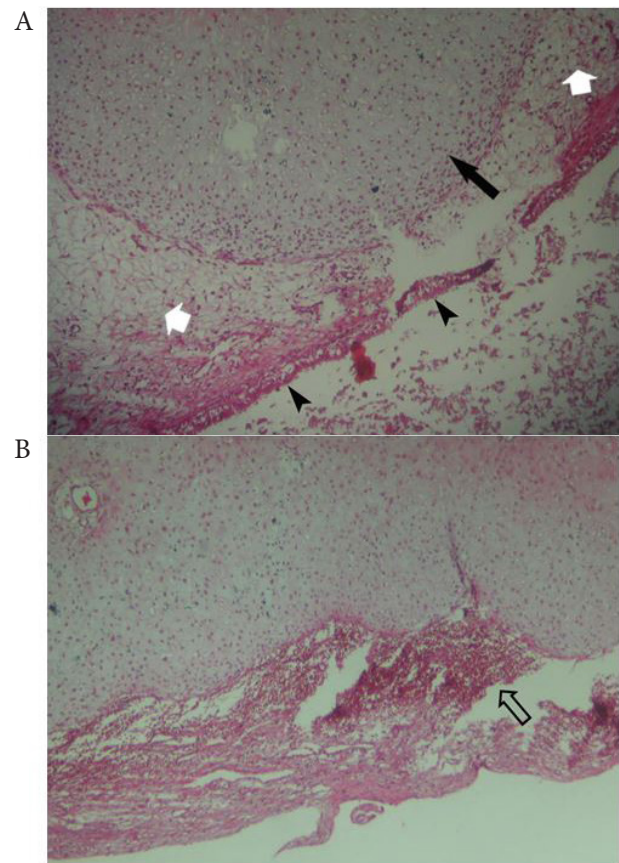


Figure 2. A: High power photomicrograph demonstrates a polypoid lesion consisting of mature hyaline cartilage (black arrow) surrounded by a loose cellular mesenchymal stromal component (myxoid stroma) (white arrows)-respiratory epithelium is also shown with arrow heads. B: An aneurysmal bone cyst-like area formation filled by blood (open arrow) is seen. (H&E, ×200)

sensation over the left globe with no limitation of motion or any sign of obvious global deviation. NCMH may move toward the skull base with intracranial extension and sometimes after local spreading and involvement of the naso- and oropharynx, oral cavity and infratemporal fossa, it can produce facial swelling, respiratory distress, feeding difficulties, obstructive sleep apnea, and otitis media (1,5). In our case, the mass was locally aggressive with thinning of the adjacent bones and limited extension to surrounding soft tissue without involving the skull base or intracranial extension.

NCMH was originally thought to be developmental or congenital (2). However, this seems unlikely at present, as there are documented cases in adults with an asymptomatic childhood with histological features and immunohistochemical staining profiles similar to those reports in very young children.

Association of NCMH with the DICER1 (Digital Information Center for Environment Research) mutation has recently been established. The DICER1 gene provides instructions for the production of a protein called Dicer. This protein helps stop tumors from growing (6). Mutation increases the risk of developing various tumors and recent reports have highlighted the association of NCMH with

pleuropulmonary blastoma (PPB) which is a rare pediatric tumor of the lung and pleura. Interestingly, PPB-associated NCMH tends to occur at older ages compared to other NCMH cases (7). Cases with DICER1-related tumors and new sino-nasal or orbital symptoms must be accurately evaluated. Some theories regarding the occurrence of this lesion in adulthood indicate that an underlying genetic predisposition along the proper environmental (such as chemokines and chronic sinusitis) or possibly hormonal stimulation for mesenchymal transitioning to chondroid tissue cause this tumor (8). These can be difficult to initially diagnose using radiography. Both CT scanning and magnetic resonance imaging (MRI) are helpful in tumor characterization and its capability for extension. In most reported cases, CT scans show a poorly defined, non-encapsulated predominantly solid and cystic heterogeneous soft tissue mass with or without calcification (50% of cases). T1-weighted MRI images show NCMH with low-signal intensity while it has high-signal intensity on T2-weighted images with strongly inhomogeneous contrast enhancement (9). The CT scan of our case revealed an isodense soft tissue density and mass-like lesion in the left nasal cavity, causing some expansion in this space without bony destruction. It also obliterated the left ostiomeatal complex, extending into the ethmoidal air cell system and draining pathways of the maxillary and frontal sinuses, causing accumulation of secretions in the cavity of these sinuses. Because of the above benign behaviors and no signs of extension beyond the borders of the left nasal cavity, MRI examination was not required.

The radiological appearance of NCMH raises suspicion for malignancy. Malignant processes are much more destructive, evidencing ill-defined borders, rapid growing nature, and bony destructions with sharp edges in radiological assessments (10). An initial accurate pathological diagnosis is very important in NCMH. Histopathological features in this tumor include irregular islands of mature and immature hyaline cartilages with or without calcification, stromal tissue with myxoid background, and no atypical mitotic figures (1,3). In immunohistochemical study, the cells of the cartilage component are strongly positive for surface antigens such as vimentin and S100 protein. The cells of the mesenchymal components are positive for vimentin (1,11). Immunohistochemical study in our case revealed stromal vimentin positive staining, and cartilage islands were positive for S100 protein.

Pathological mimickers for this tumor are chondro-myxoid fibroma, chondroblastoma and osteochondromyxoma, but the main histopathological differential diagnosis is “mesenchymal chondrosarcoma” originating from the nasal cavity. This tumor is an aggressive neoplasm usually found in skeletal locations tending for delayed distance metastasis and late recurrence.

It comprises small monotonous mesenchymal cells and islands of benign-appearing cartilage. Unlike NCMH, the mesenchymal cells are small with peripheral condensed chromatin and hyperchromatic nuclei (12). We should bear in mind the possibility of malignant transformation; therefore, detailed histological examination must be done, especially in adult cases of NCMH (13).

The main treatment for NCMH is total endoscopic resection. We excised the lesion by endoscopic surgery with appropriate dissection and minimal bleeding. Because of the mass pressure effect and loosening of middle turbinate, a part of this turbinate was also removed. Tumor relapse can occur in case of incomplete excision; however, some data suggest that the risk of recurrence cannot be absolutely eliminated by complete resection. For intracranial extension a combined intranasal–neurosurgical approach is required (2,14). Although there is a case report of pre-operative embolization (11) and some recommendations for using adjuvant chemoradiotherapy for residual tumors (15), their validity cannot be accurately determined. After surgery, we did not use any complementary treatments. There is no study that has followed up and evaluated long-term recurrence in patients who have had the lesion completely removed. In our study the patient was examined endoscopically every two months in the first year after surgery, then every four months up to 5 years. Since then, routine examinations were performed every six months. If the patient showed signs of obstruction, runny nose, etc., on either side for more than two to three weeks, a radiographic examination would be performed. Within 12 years, the patient’s nose and sinuses were evaluated for tumor regrowth or the possibility of malignant degeneration. The last CT scan showed complete resolution.

We hereby reported the 9th documented adult case of NCMH, a benign nasal tumor usually occurring during infancy. Because of overlapping histological features with multiple benign and soft tissue tumors, NCMH may be misdiagnosed. Special attention should be paid to the imaging and immunohistochemical characteristics of this neoplasm in the adult population for correct diagnosis and proper management.

Authors’ Contribution

MA diagnosed the patient and wrote the manuscript. MK performed the pathological studies. SM was consulted on the case for definitive diagnosis and follow-up. GZ revised the manuscript. All authors read and approved the final manuscript.

Availability of Data and Materials

The datasets used during the current study are available upon request.

Conflict of Interests

The authors declare that they have no competing interests.

Ethical Approval

The study received ethics approval from the Ethical Committee of

Hormozgan University of Medical Sciences and it complies with the statements of the Declaration of Helsinki.

Consent for Publication

Written informed consent was obtained from the patient for publication of this case report and any accompanying images.

Funding/Support

No funding was received.

Acknowledgments

We sincerely appreciate the dedicated efforts of the personnel of Bandar Abbas Payambar Azam Hospital.

References

- Johnson C, Nagaraj U, Esguerra J, Wasdahl D, Wurzbach D. Nasal chondromesenchymal hamartoma: radiographic and histopathologic analysis of a rare pediatric tumor. *Pediatr Radiol*. 2007;37(1):101-4. doi: 10.1007/s00247-006-0352-6.
- McDermott MB, Ponder TB, Dehner LP. Nasal chondromesenchymal hamartoma: an upper respiratory tract analogue of the chest wall mesenchymal hamartoma. *Am J Surg Pathol*. 1998;22(4):425-33. doi: 10.1097/0000478-199804000-00006.
- Mason KA, Navaratnam A, Theodorakopoulou E, Chokkalingam PG. Nasal chondromesenchymal hamartoma (NCMH): a systematic review of the literature with a new case report. *J Otolaryngol Head Neck Surg*. 2015;44(1):28. doi: 10.1186/s40463-015-0077-3.
- Moon SH, Kim MM. Nasal chondromesenchymal hamartoma with incomitant esotropia in an infant: a case report. *Can J Ophthalmol*. 2014;49(1):e30-2. doi: 10.1016/j.jcjo.2013.11.011.
- Cho YC, Sung IY, Son JH, Ord R. Nasal chondromesenchymal hamartoma: report of a case presenting with intraoral signs. *J Oral Maxillofac Surg*. 2013;71(1):72-6. doi: 10.1016/j.joms.2012.03.020.
- Stewart DR, Messinger Y, Williams GM, Yang J, Field A, Schultz KA, et al. Nasal chondromesenchymal hamartomas arise secondary to germline and somatic mutations of DICER1 in the pleuropulmonary blastoma tumor predisposition disorder. *Hum Genet*. 2014;133(11):1443-50. doi: 10.1007/s00439-014-1474-9.
- Priest JR, Williams GM, Mize WA, Dehner LP, McDermott MB. Nasal chondromesenchymal hamartoma in children with pleuropulmonary blastoma--a report from the International Pleuropulmonary Blastoma Registry. *Int J Pediatr Otorhinolaryngol*. 2010;74(11):1240-4. doi: 10.1016/j.ijporl.2010.07.022.
- Ozolek JA, Carrau R, Barnes EL, Hunt JL. Nasal chondromesenchymal hamartoma in older children and adults: series and immunohistochemical analysis. *Arch Pathol Lab Med*. 2005;129(11):1444-50. doi: 10.5858/2005-129-1444-nchioc.
- Wang T, Li W, Wu X, Li Q, Cui Y, Chu C, et al. Nasal chondromesenchymal hamartoma in young children: CT and MRI findings and review of the literature. *World J Surg Oncol*. 2014;12:257. doi: 10.1186/1477-7819-12-257.
- Morón FE, Morris MC, Jones JJ, Hunter JV. Lumps and bumps on the head in children: use of CT and MR imaging in solving the clinical diagnostic dilemma. *Radiographics*. 2004;24(6):1655-74. doi: 10.1148/rg.246045034.
- Finitsis S, Giavroglou C, Potsi S, Constantinidis I, Mpaltatzidis A, Rachovitsas D, et al. Nasal chondromesenchymal hamartoma in a child. *Cardiovasc Intervent Radiol*. 2009;32(3):593-7. doi: 10.1007/s00270-008-9458-6.
- Knott PD, Gannon FH, Thompson LD. Mesenchymal chondrosarcoma of the sinonasal tract: a clinicopathological study of 13 cases with a review of the literature. *Laryngoscope*. 2003;113(5):783-90. doi: 10.1097/00005537-200305000-00004.
- Li Y, Yang QX, Tian XT, Li B, Li Z. Malignant transformation of nasal chondromesenchymal hamartoma in adult: a case report and review of the literature. *Histol Histopathol*. 2013;28(3):337-44. doi: 10.14670/hh-28.337.
- Nakagawa T, Sakamoto T, Ito J. Nasal chondromesenchymal hamartoma in an adolescent. *Int J Pediatr Otorhinolaryngol Extra*. 2009;4(3):111-3. doi: 10.1016/j.pedex.2008.09.002.
- Shet T, Borges A, Nair C, Desai S, Mistry R. Two unusual lesions in the nasal cavity of infants--a nasal chondromesenchymal hamartoma and an aneurysmal bone cyst like lesion. More closely related than we think? *Int J Pediatr Otorhinolaryngol*. 2004;68(3):359-64. doi: 10.1016/j.ijporl.2003.10.014.