

⇒ Research Article



Vitamin A for the Prevention of Renal Parenchymal Injury in Children With Acute Pyelonephritis: An assessor-blind Randomized Controlled Trial

Kambiz Ghasemi¹ , Maryam Esteghamati¹ , Seyed Mahmood Ahmadi Koupaie² ¹Department of Pediatric Nephrology, Clinical Research Development Center of Children's Hospital, Hormozgan University of Medical Sciences, Bandar Abbas, Iran²Student Research Committee, Faculty of Medicine, Hormozgan University of Medical Sciences, Bandar Abbas, Iran**Abstract**

Background: To date, limited studies have evaluated the role of vitamin A in acute pyelonephritis (APN). Accordingly, we aimed to investigate the effect of this vitamin on the prevention of renal damage in children with APN.

Methods: This assessor-blind randomized controlled trial included 108 children with APN, aged 3 months to 14 years, who were admitted to Bandar Abbas Children's Hospital, Bandar Abbas, Iran, in 2020. Patients were randomly allocated to two equal groups. Children in the vitamin A group received vitamin A in addition to antibiotics (ceftriaxone), while those in the control group only received antibiotics. Then, children in both groups underwent dimercaptosuccinic acid (DMSA) scanning once at baseline and four months after treatment. Photopenic areas in the DMSA scan were regarded as damaged areas. Further, serum vitamin A levels, C-reactive protein (CRP) levels, and erythrocyte sedimentation rate (ESR) were measured in all participants before the initiation of treatment. Finally, the demographic features of the participants were noted, including age and gender.

Results: Patients in both groups were comparable regarding age and sex. Serum vitamin A levels, CRP, and ESR did not differ significantly between groups before treatment. The mean number of photopenic areas in the baseline DMSA scan was similar in both groups ($P=0.481$); however, the mean number of photopenic areas in the DMSA scan after four months was significantly lower in the vitamin A group compared to controls ($P=0.004$).

Conclusion: Therefore, the use of vitamin A, along with antibiotics can significantly decrease renal damage in children with APN.

Keywords: Pyelonephritis, Children, Vitamin A, Renal scar

***Correspondence to**

Kambiz Ghasemi,
Tel: +989177611468,
Email: kambizghassemi@
yahoo.com



Received July 12, 2021, Accepted: September 6, 2021, Published Online: October 10, 2022

Background

Urinary tract infection (UTI), the most common infection of the urogenital system, is regarded as one of the most frequent infections in childhood (1). It can occur in two forms, namely, cystitis and acute pyelonephritis (APN). Delay in treating the acute infection can lead to injury to the renal parenchyma, which is also called renal scarring (2, 3). With incidence rates ranging from 5 to 57% following APN, renal scarring can result in progressive kidney damage (4).

The timely treatment of APN is of utmost importance since severe scarring can occur even after the first episode of kidney infection (5). As demonstrated in a multicenter study, mere antibiotics administration was not effective in the prevention of renal scarring in children with APN (6). With inflammation and oxidative stress as the potential underlying mechanisms of renal damage in APN, antioxidants or anti-inflammatory agents appear to decrease the risk of renal scarring (7). Backed up by

animal studies, vitamins have shown promising results in this regard (8, 9); nonetheless, there are limited studies on the effects of vitamins on kidney scarring in humans (7). Vitamin A and B-carotene have anti-inflammatory and antioxidant properties (10). It has also been reported that vitamin A can contribute to the re-epithelialization of injured mucosal surfaces (11, 12). Nevertheless, contradictory results have been demonstrated on the effects of vitamin A on renal scarring (7, 12, 13).

Objectives

Thus, this study aimed to evaluate the role of vitamin A in the prevention of renal damage in children with APN.

Methods**Participants**

The current assessor-blind randomized controlled trial included 108 children with suspected APN (based on clinical findings and positive urine culture) aged three

months to 14 years admitted to Bandar Abbas Children's Hospital, Bandar Abbas, Iran from January 1, 2020, to September 20, 2020. The inclusion criterion was positive culture ($\geq 10^5$ CFU/mL in bagged specimens, $\geq 10^4$ CFU/mL in catheterized specimens, or $\geq 10^2$ CFU/mL in suprapubic aspirations). Patients who had anatomical disorders of the urinary system were excluded from the study. The sample size was calculated as at least 108 participants based on $\alpha = 0.05$, and $\beta = 0.1$.

Study Design

First, written informed consent was obtained from the parents or guardians of the children. The age and sex of the participants were recorded as well. A random venous blood sample was collected from all the children before treatment for the measurement of serum vitamin A, C-reactive protein (CRP), and erythrocyte sedimentation rate (ESR). Serum vitamin A was measured using the high-performance liquid chromatography method (Younglin device, Korea).

Patients were randomly assigned to two equal groups (54 in the vitamin A group and 54 as controls) using simple randomization by randomly generated numbers produced by the Random Allocation software. Details of patient enrollment, randomization, and analysis are

depicted in Figure 1. Children in both groups received 50-75 mg/kg of intravenous ceftriaxone daily. In addition to ceftriaxone, children in the vitamin A group received 25 000 and 50 000 units of intramuscular vitamin A (Osvah Pharmaceutical Co., Iran) if they were younger than 1 year and ≥ 1 year on their first day of admission, respectively. Children in both groups received 8 mg/kg oral cefixime daily after discharge.

All children underwent dimercaptosuccinic acid (DMSA) scanning using the Siemens E.Cam® single-head scanner once before treatment and four months after treatment. DMSA scans were evaluated by an experienced pediatric nephrologist who was blinded to the grouping of patients. Photopenic areas in the DMSA scan were regarded as damaged areas.

Data Analysis

The Statistical Package for the Social Sciences (SPSS) software (version 26.0, Armonk, NY: IBM Corp., USA) was used for data analysis. Mean, standard deviation, frequency, and percentages were applied to describe the variables. Based on the results of the Kolmogorov-Smirnov test, continuous and categorical variables were compared between groups using the Mann-Whitney and chi-square tests, respectively. Further, the Wilcoxon test

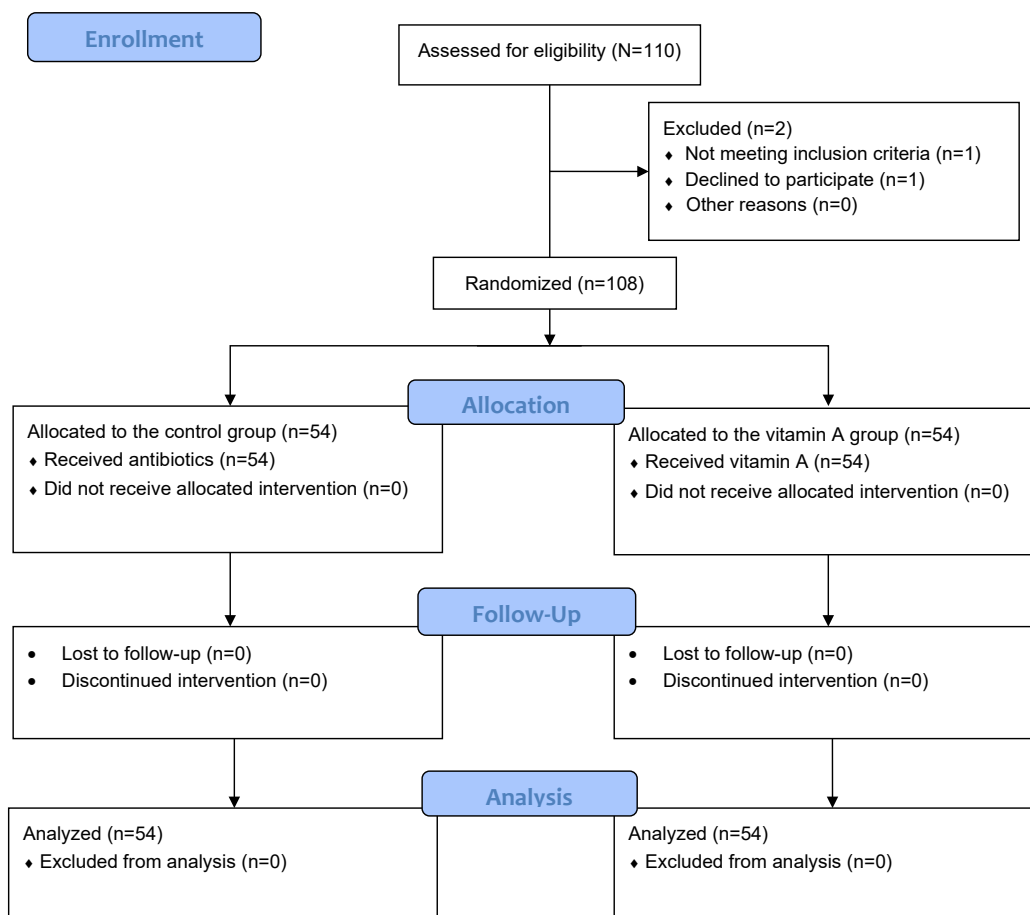


Figure 1. CONSORT Flow Diagram.

was employed to compare the mean number of photopenic areas on DMSA scans before and after treatment, and *P* values ≤ 0.05 were considered statistically significant.

Results

Of the 108 children included in this study with a mean age of 5.63 ± 2.24 years, 52 (48.1%) were boys and the remaining 56 (51.9%) were girls. Table 1 presents the comparison of demographic features between groups. Children in the vitamin A and control groups were comparable in terms of age ($P=0.914$) and sex ($P=1.000$).

Baseline serum vitamin A levels, CRP, and ESR did not differ significantly between groups ($P=0.152$, $P=0.064$, and $P=0.393$, respectively, Table 2). Likewise, there was no statistically significant difference between the vitamin A and control groups regarding the mean number of photopenic areas in the baseline DMSA scan ($P=0.481$). The mean number of photopenic areas significantly decreased in both groups in the follow-up DMSA; however, this reduction was higher in the vitamin A group (Table 3). Figures 2 and 3 demonstrate the number of photopenic areas in the baseline and follow-up DMSA scans in both groups.

Discussion

In the current study, it was found that vitamin A can reduce renal scarring in children with APN. The follow-up DMSA scan, performed four months after treatment,

Table 1. Comparison of Demographic Features Between the Vitamin A and Control Groups

Variables	Control (n=54)	Vitamin A (n=54)	P Value
Age (y), mean \pm SD	5.68 \pm 2.36	5.59 \pm 2.14	0.914 ^a
Sex, No. (%)			
Male	26 (48.1)	26 (48.1)	1.000 ^b
Female	28 (51.9)	28 (51.9)	

Note. N: Number; SD: Standard deviation. ^aAnalyzed by Mann-Whitney test. ^bAnalyzed by Chi-square test.

Table 2. Comparison of Baseline Serum Vitamin A, CRP, and ESR Between Groups

Variables	Control (n=54)	Vitamin A (n=54)	P Value ^a
Vitamin A ($\mu\text{mol/L}$), mean \pm SD	0.35 \pm 0.16	0.30 \pm 0.21	0.152
CRP (mg/L), mean \pm SD	21.04 \pm 4.37	23.74 \pm 8.02	0.064
ESR (mm/h), mean \pm SD	35.83 \pm 14.82	38.61 \pm 16.89	0.393

Note. N: Number; SD: Standard deviation; CRP: C-reactive protein; ESR: Erythrocyte sedimentation rate. ^aAnalyzed by Mann-Whitney test.

Table 3. Comparison of Baseline and Follow-up DMSA Results Between Groups

Variables	Control (n=54)	Vitamin A (n=54)	P Value ^a
Baseline DMSA (number of photopenic areas), mean \pm SD	2.00 \pm 0.99	1.83 \pm 0.69	0.481
DMSA at 4 months (number of photopenic areas), mean \pm SD	0.35 \pm 0.56	0.09 \pm 0.29	0.004
P value ^b	<0.001	<0.001	

Note. N: Number; SD: Standard deviation; DMSA: Dimercaptosuccinic acid. ^aAnalyzed by Mann-Whitney test; ^bAnalyzed by Wilcoxon test.

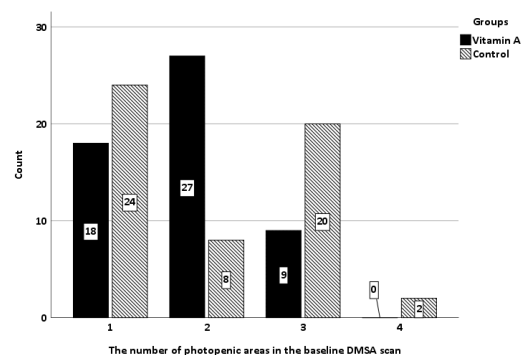


Figure 2. Comparison of the Number of Photopenic Areas in the Baseline DMSA Scan Between the Vitamin A and Control Groups. Note. DMSA: Dimercaptosuccinic acid.

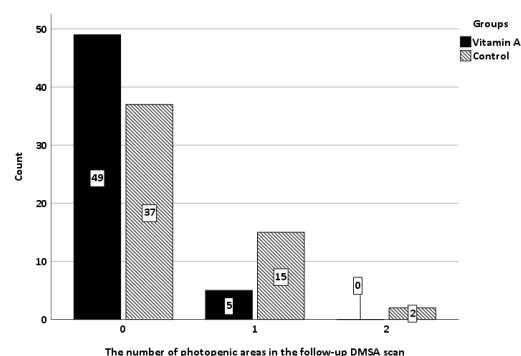


Figure 3. Comparison of the Number of Photopenic Areas in the Follow-up DMSA Scan Between the Vitamin A and Control Groups. Note. DMSA: Dimercaptosuccinic acid.

showed a significantly lower number of photopenic areas in the vitamin A group compared to controls, which is in line with the results of Kabhazi et al. They evaluated the efficacy of vitamin A plus antibiotics for the improvement of UTI symptoms and prevention of renal scarring in girls with APN. In their study, the worsening of renal lesions in the second DMSA scan was significantly lower with vitamin A compared to placebo. Further, 63.8% of the patients in the vitamin A group had improvements in the number of photopenic areas, while the corresponding percentage in the placebo group was 21% (4). Similarly, Zhang et al concluded that vitamin A is inversely correlated with renal parenchymal injury (7). On the other hand, the findings of Dalirani et al are consistent with those of our study. They investigated the role of vitamin A in the prevention of renal scars following APN and reported significantly lower progression of renal damage and scars in the vitamin A group in comparison with controls (12). Moreover, Ayazi et al demonstrated significantly lower permanent renal damage with vitamin

A (13). The results of Yilmaz et al are also in conformity with our findings (14).

Although Sobouti et al compared vitamin A and E supplementation for the reduction of renal scars secondary to APN and found comparable results with both vitamins, the effect of vitamin E was more promising compared to vitamin A (15). This indicates that in future studies, other vitamins should be compared with vitamin A for the prevention of renal scarring in APN. Yousefichaijan et al evaluated the effect of vitamin A on the clinical presentations of recurrent APN in children. Although they did not study renal parenchymal damage, they reported that vitamin A administration led to a significant decrease in urinary symptoms and fever. Additionally, they concluded that vitamin A can be used for the treatment of children with APN (2).

In general, the results of a limited number of studies evaluating the role of vitamin A in APN conform to and confirm our results. Therefore, it appears that vitamin A is beneficial for the prevention of renal scars in children with APN or the reduction of the already-formed scars in the acute phase of the infection. Of note, the strength of the current study, compared to previous studies, was that both groups of our study were comparable regarding the demographic features, as well as baseline serum vitamin A levels, CRP, and ESR, which limits the potential confounding effects of these factors on the results.

Nonetheless, this study was not without limitations. The sample size was relatively small, which can restrict the generalizability of our findings. Future studies with a larger sample size are required to confirm our results.

Conclusion

In the current study, vitamin A was effective for the prevention of renal scarring in children with APN. Thus, we recommend the administration of a single dose of intramuscular vitamin A in children with APN to avoid or reduce the severity of renal scarring.

Acknowledgments

We would like to express our sincere gratitude toward the investigators, coordinators, volunteer patients and their parents/guardians, and the personnel of Bandar Abbas Children's Hospital, Hormozgan, Iran.

Authors' Contribution

Conceptualization and study validation: KG. Study supervision: ME. Implementation: SMAK. Data analysis and interpretation: SMAK. Writing and reviewing: KG. All the authors have read and approved the manuscript.

Availability of Data and Materials

The datasets used and/or analyzed during the current study are available from the corresponding author on reasonable request.

Conflict of Interests

The authors declare that they have no competing interests.

Ethics Approval

The study received ethics approval from the Ethics Committee of Hormozgan University of Medical Sciences (ethics code: IR.HUMS.REC.1399.313) and it complies with the statements of the Declaration of Helsinki. Written informed consent was obtained from the parents/guardians of the participants.

Funding/Support

The study was financially supported by Hormozgan University of Medical Sciences.

References

1. Yousefi Chaijan P, Sharafkhan M. A comparison between bacterial resistance to common antibiotics in breast-fed and bottle-fed female infants with urinary tract infection. *Arch Clin Infect Dis*. 2012;7(4):113-5. doi: [10.5812/archcid.15090](https://doi.org/10.5812/archcid.15090).
2. Yousefichaijan P, Kahbazi M, Rasti S, Rafeie M, Sharafkhan M. Vitamin E as adjuvant treatment for urinary tract infection in girls with acute pyelonephritis. *Iran J Kidney Dis*. 2015;9(2):97-104.
3. Taneja N, Chatterjee SS, Singh M, Singh S, Sharma M. Pediatric urinary tract infections in a tertiary care center from north India. *Indian J Med Res*. 2010;131:101-5.
4. Kahbazi M, Sharafkhan M, Yousefichaijan P, Taherahmadi H, Rafiei M, Kaviani P, et al. Vitamin A supplementation is effective for improving the clinical symptoms of urinary tract infections and reducing renal scarring in girls with acute pyelonephritis: a randomized, double-blind placebo-controlled, clinical trial study. *Complement Ther Med*. 2019;42:429-37. doi: [10.1016/j.ctim.2018.12.007](https://doi.org/10.1016/j.ctim.2018.12.007).
5. Leroy S, Chalumeau M, Ulinski T, Dubos F, Sergeant-Alaoui A, Merzoug V, et al. Impressive renal damage after acute pyelonephritis in a child. *Pediatr Nephrol*. 2010;25(7):1365-8. doi: [10.1007/s00467-010-1461-x](https://doi.org/10.1007/s00467-010-1461-x).
6. Bouissou F, Munzer C, Decramer S, Roussel B, Novo R, Morin D, et al. Prospective, randomized trial comparing short and long intravenous antibiotic treatment of acute pyelonephritis in children: dimercaptosuccinic acid scintigraphic evaluation at 9 months. *Pediatrics*. 2008;121(3):e553-60. doi: [10.1542/peds.2006-3632](https://doi.org/10.1542/peds.2006-3632).
7. Zhang GQ, Chen JL, Zhao Y. The effect of vitamin A on renal damage following acute pyelonephritis in children: a meta-analysis of randomized controlled trials. *Pediatr Nephrol*. 2016;31(3):373-9. doi: [10.1007/s00467-015-3098-2](https://doi.org/10.1007/s00467-015-3098-2).
8. Sadeghi Z, Kajbafzadeh AM, Tajik P, Monajemzadeh M, Payabvash S, Elmi A. Vitamin E administration at the onset of fever prevents renal scarring in acute pyelonephritis. *Pediatr Nephrol*. 2008;23(9):1503-10. doi: [10.1007/s00467-008-0853-7](https://doi.org/10.1007/s00467-008-0853-7).
9. Emamghorashi F, Owji SM, Motamedifar M. Evaluation of effectiveness of vitamins C and E on prevention of renal scar due to pyelonephritis in rat. *Adv Urol*. 2011;2011:489496. doi: [10.1155/2011/489496](https://doi.org/10.1155/2011/489496).
10. Reifen R, Levy E, Berkovich Z, Tirosh O. Vitamin A exerts its antiinflammatory activities in colitis through preservation of mitochondrial activity. *Nutrition*. 2015;31(11-12):1402-7. doi: [10.1016/j.nut.2015.05.011](https://doi.org/10.1016/j.nut.2015.05.011).
11. Kaetzel CS. The polymeric immunoglobulin receptor: bridging innate and adaptive immune responses at mucosal surfaces. *Immunol Rev*. 2005;206:83-99. doi: [10.1111/j.0105-2896.2005.00278.x](https://doi.org/10.1111/j.0105-2896.2005.00278.x).
12. Dalirani R, Yousefi Zoshk M, Sharifian M, Mohkam M, Karimi A, Fahimzad A, et al. Role of vitamin A in preventing

- renal scarring after acute pyelonephritis. *Iran J Kidney Dis.* 2011;5(5):320-3.
13. Ayazi P, Moshiri SA, Mahyar A, Moradi M. The effect of vitamin A on renal damage following acute pyelonephritis in children. *Eur J Pediatr.* 2011;170(3):347-50. doi: [10.1007/s00431-010-1297-1](https://doi.org/10.1007/s00431-010-1297-1).
 14. Yilmaz A, Bahat E, Yilmaz GG, Hasanoglu A, Akman S, Guven AG. Adjuvant effect of vitamin A on recurrent lower urinary tract infections. *Pediatr Int.* 2007;49(3):310-3. doi: [10.1111/j.1442-200X.2007.02370.x](https://doi.org/10.1111/j.1442-200X.2007.02370.x).
 15. Sobouti B, Hooman N, Movahed M. The effect of vitamin E or vitamin A on the prevention of renal scarring in children with acute pyelonephritis. *Pediatr Nephrol.* 2013;28(2):277-83. doi: [10.1007/s00467-012-2308-4](https://doi.org/10.1007/s00467-012-2308-4).